

Case Presentation



- Case History
- disease
- preoperatively therapy
- pre- and postoperativ MRI
- result

Medical history

Case 1:

R.W. male, age 56

Former Triathlete, Power lifting, slim, trained,
Lumbago since 1998, outpatient therapy since
2009, PT,

Nevertheless slow deterioration

2012 LI b. NPP L4/5 li., PRT L5 left with
ischialgie improvement, further deterioration
Lumbago

Therapie

Case 1:

next visit 2015, not able to do sports!

MRT 04/15 see slide 4 and 6

Decision for Fehrfix surgery

L4/5 u. L5/S1, 30.10.15

Postop. quick improvement, able to do sports again by end of the year 2015

rasche

Therapie

Case 1:

based on impressive improvement over 60%
decision for FehrFix Implantation L3/4.

L 3/4, postop. MRI 16/1/16 slide 7 and 8.

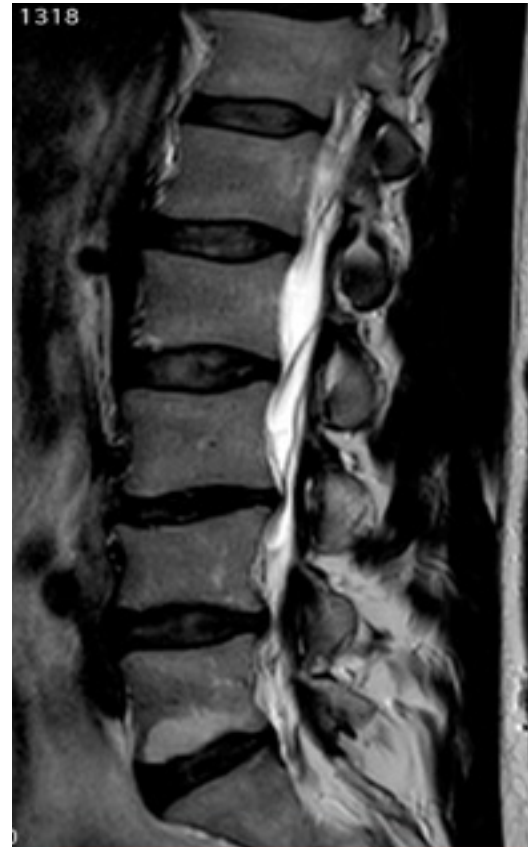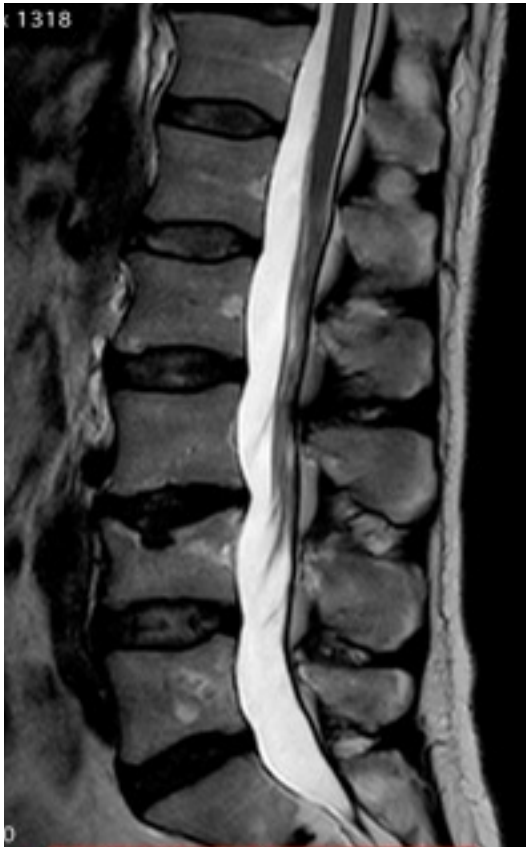FehrFix Implantation 16/2/16 L3/4 further
improvement but less the after first
Implantation.

Patient is very satisfied and able to do
sports!!

Case presentation



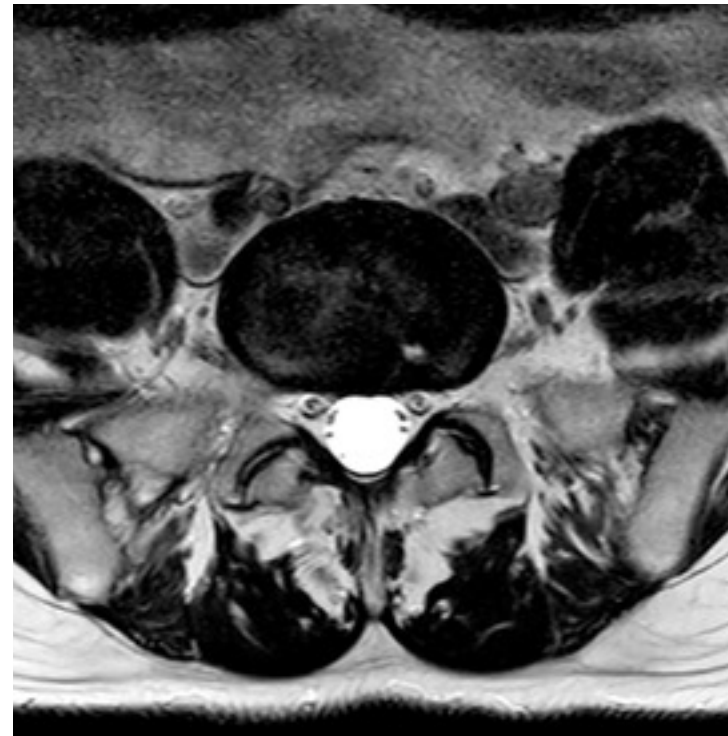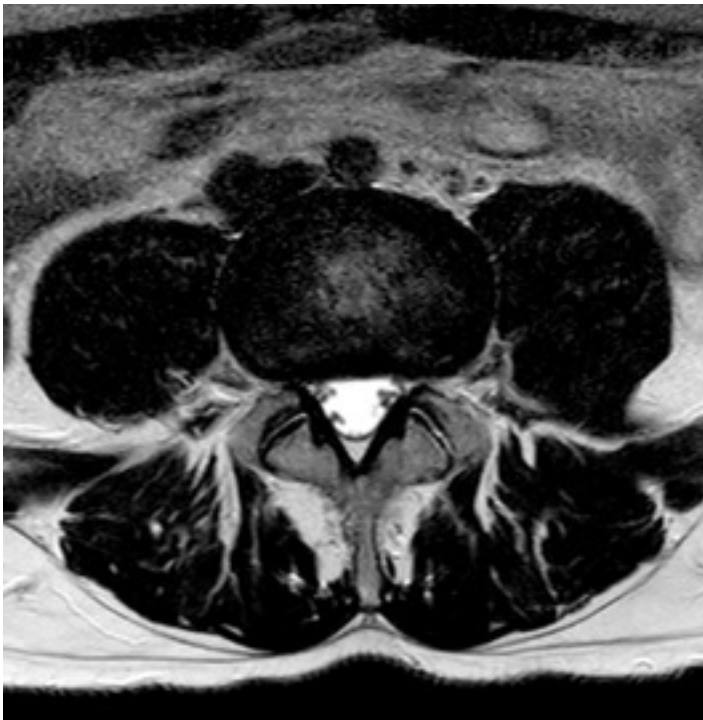Preoperative sagittal MRI in different layers



Case Presentation



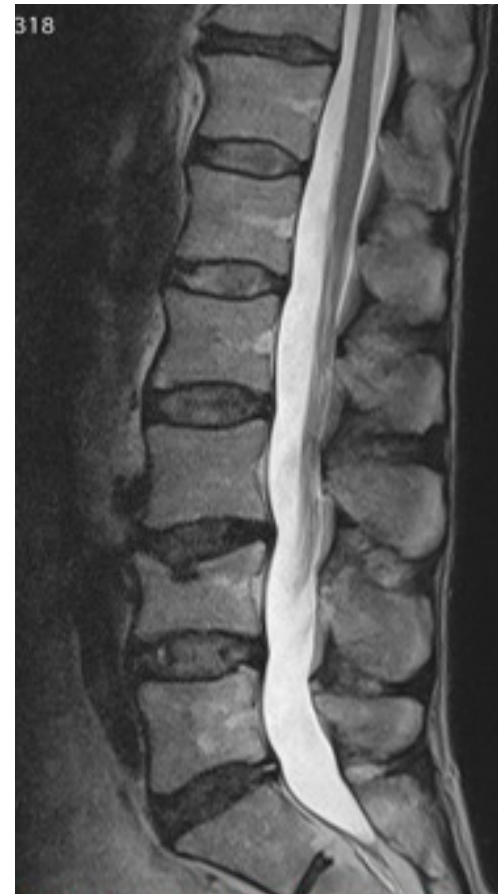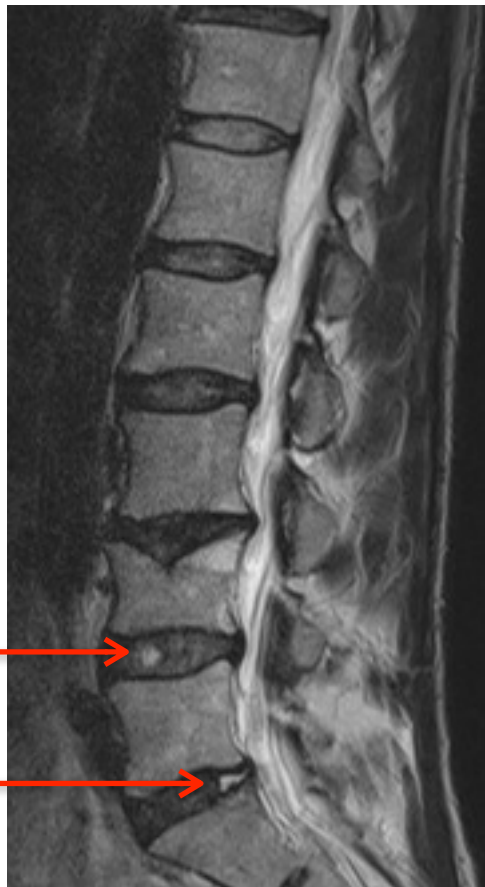
Preoperative transversal MRI L4/5 and L5/S1



Case Presentation



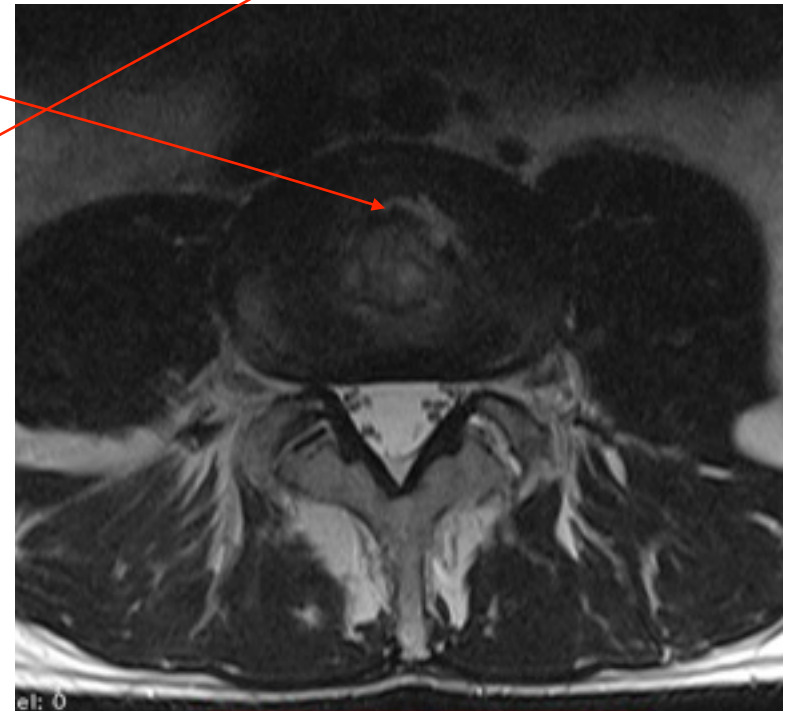
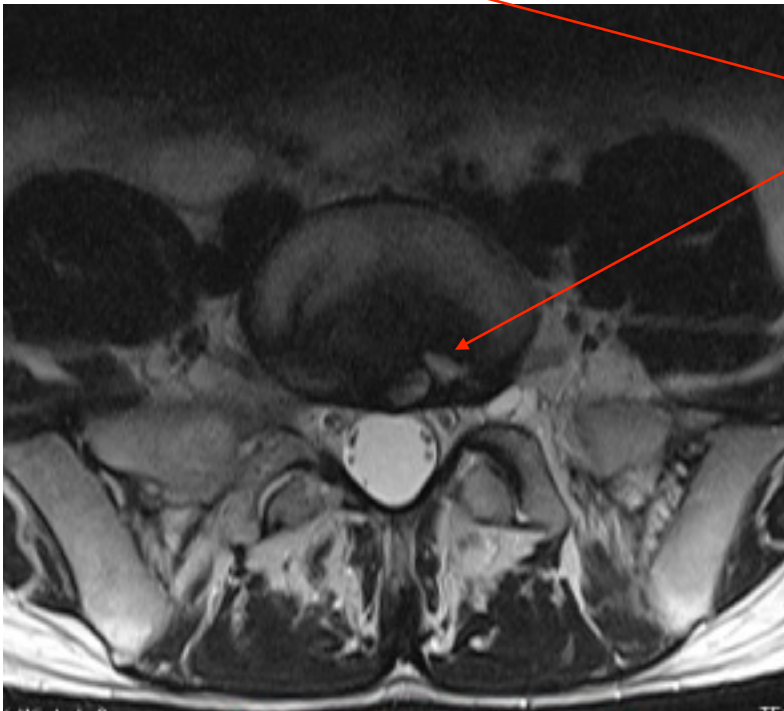
Postoperative T2 sagittal MRI with visible Implantat L4/5 and L5/S1



Case Presentation



Postoperatively T2 transversal MRI L5/S1 und L4/5 with visible Implantat



Case Presentation



Pre- and postoperatively MRI T1 sagittal

